Semi-Annual Report
January 15, 2002

PROJECT IDENTIFIERS

Award Number - NA16FX1417

Grant Program/CFDA# - Steller Sea Lion Research Initiative: 11-439

Recipient Organization - Colorado State University

Principal Investigator - A. Wendell Nelson DVM, MS, PhD

Project Title - A Study to Evaluate Transmitter Implant Methodology

Funding - Federal: $ 331,444.00

Award Period – From: July 1, 2001 To: June 30, 2003

Period Covered by this Report – From: July 1, 2001 To: December 31, 2001

PROJECT SUMMARY

The project was directed to investigate implant methodology in sheep that would result in the development of techniques to implant transmitters in Steller Sea Lions to allow long-term tracking of these free ranging animals. The study is concentrating on transmitters with percutaneous antennae and transmitters and antennae completely buried under the skin. The goal is to produce a Steller Sea Lion monitoring system that would provide data acquisition via satellite transmission for a period of four to five years.

SUMMARY OF PROGRESS AND RESULTS

The current phase of the project is concentrating on the percutaneous antenna with a transmitter in a subcutaneous position. A subcutaneous epithelial lined cavity ("pouch") was created on the dorsal thoracic region in each of six adult sheep and allowed to heal (Figures I – IV). A mock transmitter with an antenna was implanted in each pouch. Two pouches received mock transmitters at 10 weeks; two at 8 weeks and two at 5 weeks after the pouches were created.

Biopsies were taken from the pouch epithelial lining from two sheep at four weeks and ten weeks; two sheep at eight weeks and two sheep at five weeks after the pouches were created. Excellent epithelialization was obtained with both skin and oral mucosal grafts by five weeks (Figures V – IX). Occasional small areas of ulceration of the mucous membrane and skin lining the pouch were noted. The majority (>90%) of the grafted mucous membrane and skin grafts survived and

the graft bed between segments of the mesh grafts became completely covered with epithelium by four weeks. Twenty per cent of the pouch wall from sheep # 1 under went pressure necrosis after implantation of the mock transmitter exposing the surface of the epoxy. This was due to a slightly small pouch and resulting stretch of the skin over the transmitter base (Figure X). The mock transmitter remains in place. Sheep #2 developed a stitch abscess and a small (5mm) fistula into the pouch. Other pouches are functioning well at 35 days post transmitter implantation (Figure XI). The skin around the antenna port has contracted leaving a 0 to 4 mm opening between the antenna mount and the skin edge in five sheep and a 0 to 12mm opening in one sheep (Figure XII).

PROBLEMS

The surgical procedure to create the pouch as currently designed takes about three hours and a second surgery to implant the mock transmitter takes about 1.5 hours. The shortest interim between the two surgeries was five weeks. We now know that the pouch can be created and implanted in a four week time period but this is still a long time to keep young sea lions in captivity while they get transmitters implanted. In response to this, we plan to try one stage; one-week two stages and two week two stage transmitter implant procedures using a total of six sheep. The results we get with the shorter staging procedures will be compared with epithelial lining produced and epithelial resistance to wear by the implanted transmitter of the initial six sheep implants. Additional pouch studies based on our results will be done until we have two models that will fit sea lion monitoring needs.

A well-tuned antenna/transmitter is being developed by Wildlife Computers in Seattle Washington and this will be tested as a totally implanted system in March or April of 2002. Other acceptable systems have not been found to test at this time.

At this time there are no anticipated changes in the budget for the first year of the grant. We may have to allocate more of our funding to pouch studies than originally projected but, with your permission, we should have some funds available in other categories to reallocate for this purpose.

Prepared by: _____ Date: _____

A. Wendell Nelson DVM, PhD

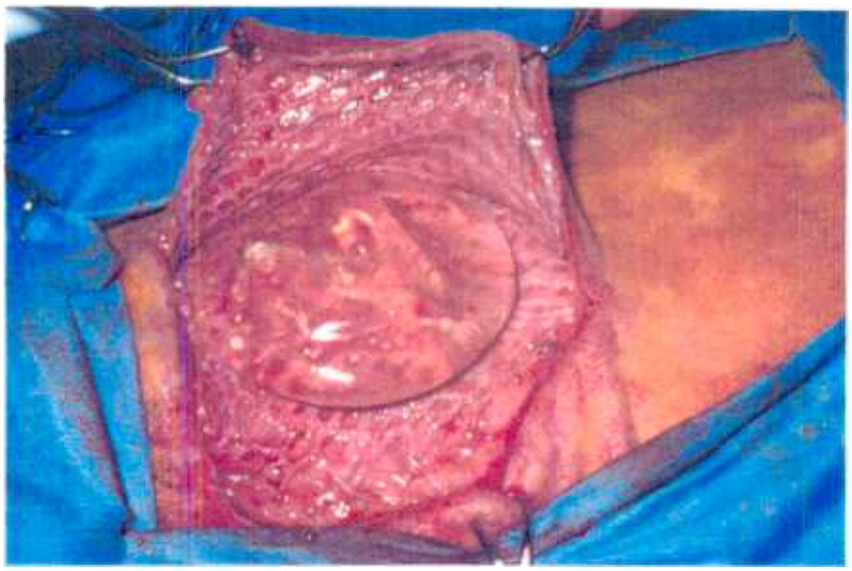

Figure I. A skin and subcutaneous tissue flap has been raised and the surface of the flap and exposed deep tissue has been covered with a meshed full thickness skin graft. A tissue expanding inflatable balloon has been placed between the two grafted surfaces. The edges of the skin and deep tissues are ready to be sutured together creating a pouch. The balloon is completely inflated after the pouch has been closed to maintain space for the transmitter while tissue healing takes place.

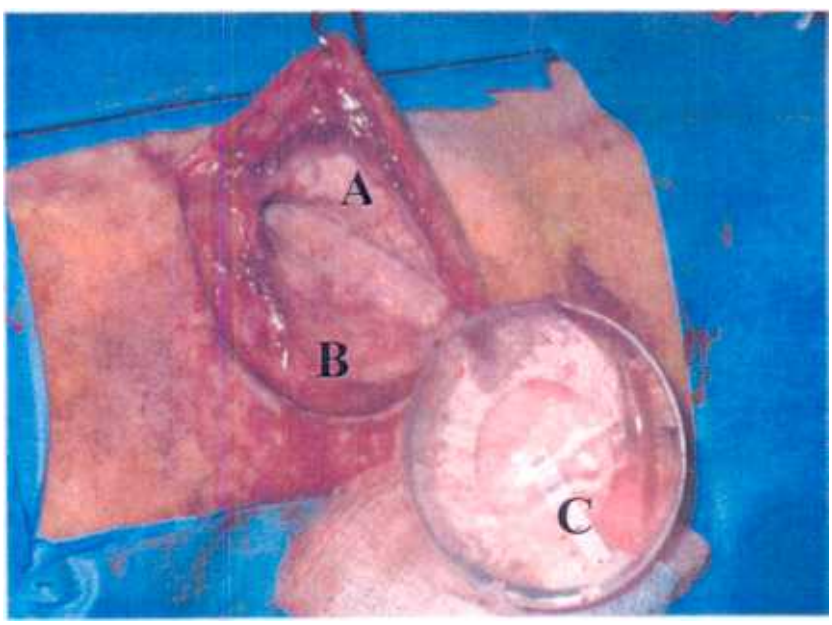

Figure II. The pouch on sheep three has been surgically opened. The epithelial covered surface of the pouch is shown with the cornified skin graft (A) and the noncornified oral mucosa graft (B) identified. The inflated balloon (C) has been removed from the pouch.

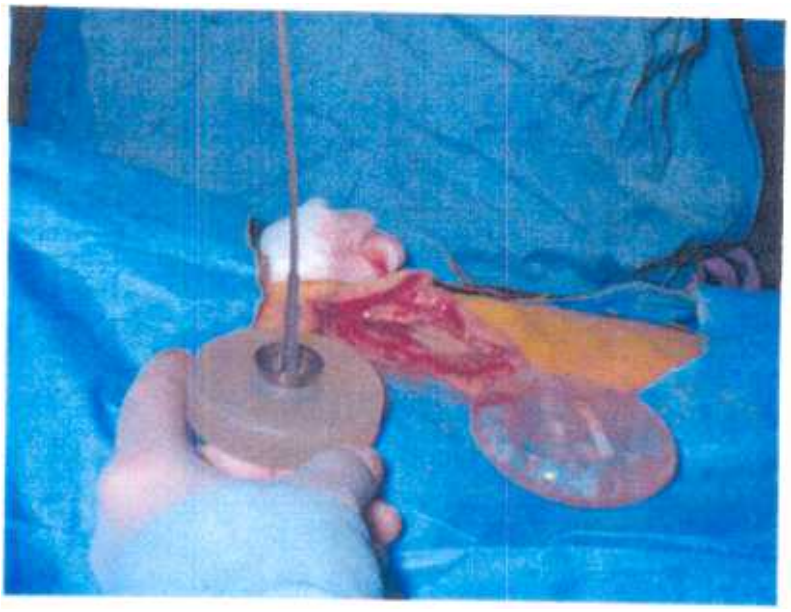

Figure III. The mock transmitter and tissue expander are shown for size comparison just prior to insertion of the transmitter into the pouch. The titanium base of the antenna assembly is used to protect the pouch stoma from the motion of the antenna and dampen motion forces.

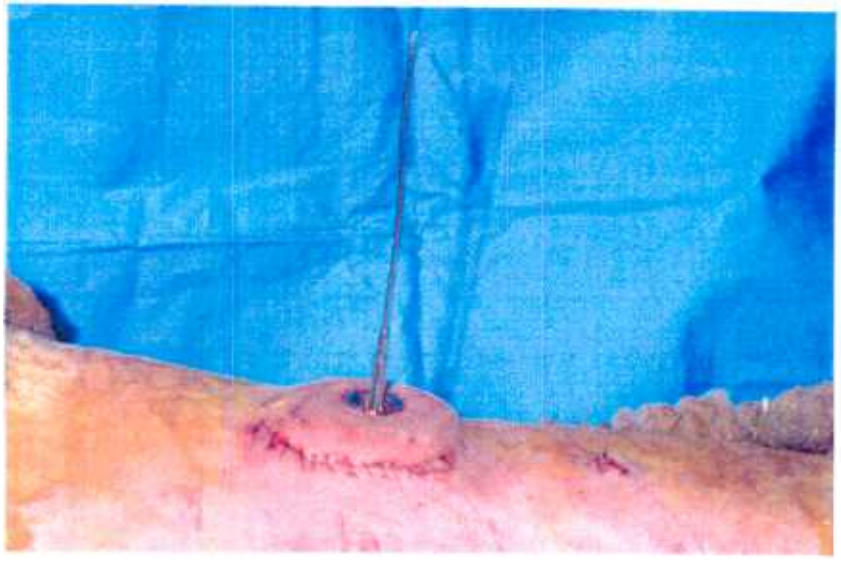

Figure IV. The mock transmitter is implanted in the pouch and the antenna is shown extending from the pouch through the surgically created stoma. The pouch epithelial lining and wooled skin edges were sutured together to form a continuous epithelialized surface all around the edge of the antenna base.

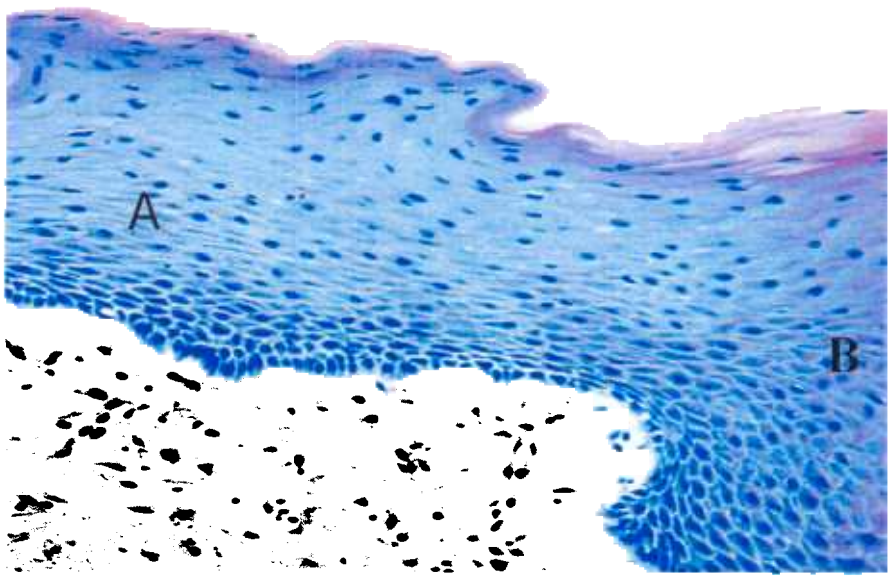

Figure V. Biopsy of the oral mucosal graft implanted for 4 weeks in the pouch of sheep number one. The histology demonstrates the originally grafted mucosa (B) has survived intact and graft epithelial cells have proliferated (A) and spread over the graft bed between segments of the mesh graft. A very thick layer of mucosal epithelial cells (compared to the skin epithelial cells) has been produced between segments of the graft and a well-defined germinal layer has been established.

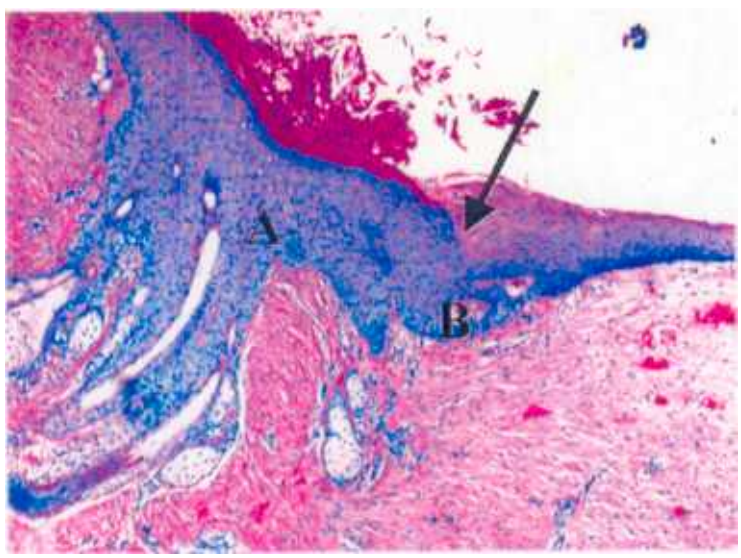

Figure VI. Biopsy of the oral mucosa and skin grafts placed in the pouch of sheep one10 weeks after grafting. This histology demonstrates the junction of healed skin graft (A) and new epithelial cells from skin and oral mucosa (B). The thick segment of skin graft including original glands and hair follicles remain healthy and epithelial cells from skin and mucosa have proliferated and spread over the non-epithelialized graft bed until they met (arrow).

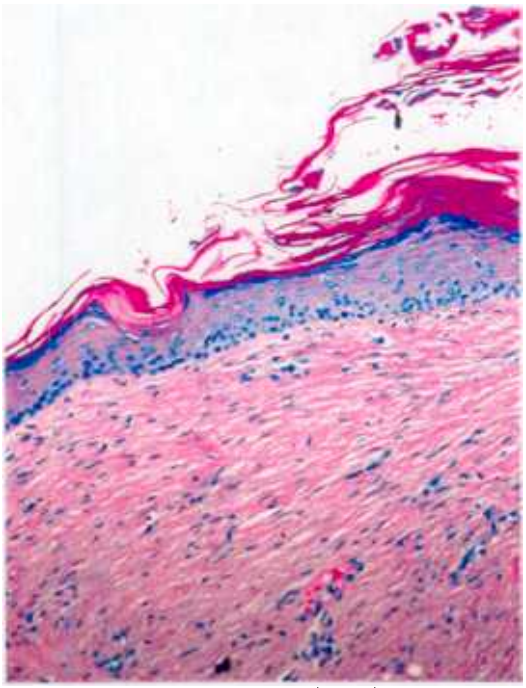

Figure VII. Biopsy of the skin graft with new epithelial growth between grafted points in the pouch of sheep one at 4 weeks after grafting. The histology demonstrates epithelial coverage with about six layers of cells without a well-organized germinal layer. Numerous young cell are distributed along the germinal or basal layer. A cornified layer is already well defined.

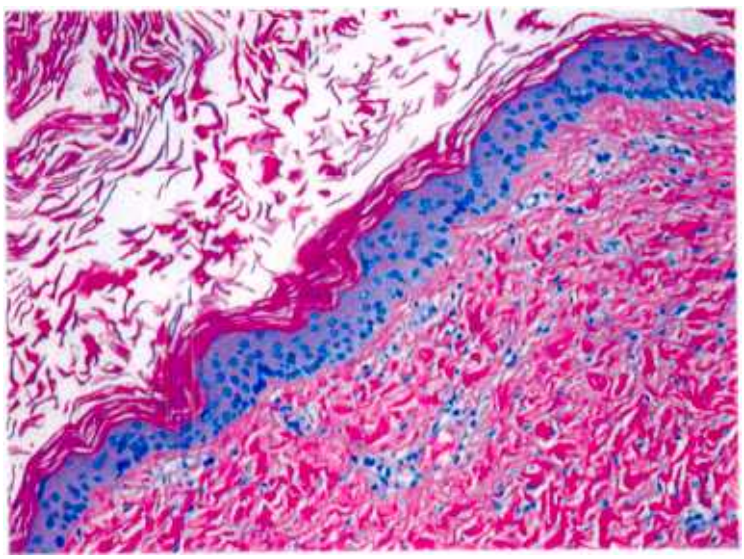

Figure VIII. Biopsy of the skin graft with new epithelial cell growth between grafted points in the pouch of sheep one at 10 weeks after grafting. The histology demonstrates epithelial coverage with about five layers of cells with a well-defined germinal cell layer. The epithelial cells have more cytoplasm and well-defined and healthy nuclei than at 4 weeks. Active cell turnover is evidenced by the well-developed cornified layer and active desclimation or cornified cells.

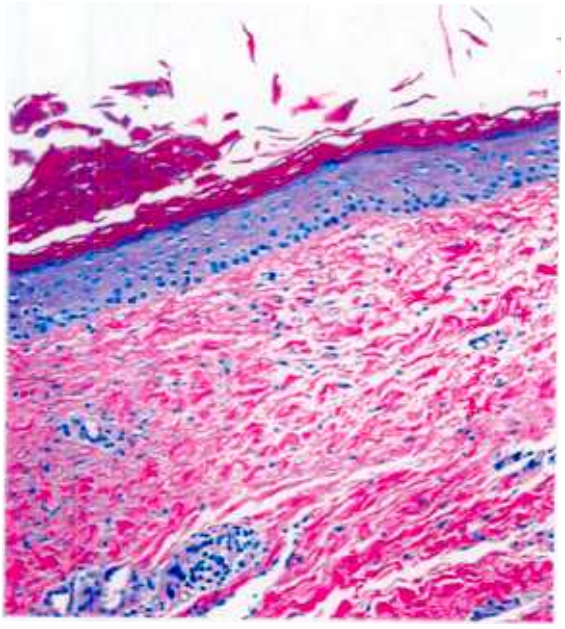

Figure IX. Biopsy of the skin graft from the roof of the pouch with new epithelial cell growth between grafted points in the pouch of sheep one at 10 weeks after grafting. The histology demonstrates new epithelial coverage with about four layers of cells and a well-defined germinal cell layer. This demonstrates the similarity of the new epithelium in both the roof and the floor of the pouch.

Figure X. Photograph of sheep #1 showing the loss of a portion of the pouch wall from pressure necrosis. The internal and external epithelial surfaces are healing together retaining the mock antenna in place.

Figure XI. Photograph of sheep # 2 showing a developing small breakdown in the pouch wall secondary to a surgical stitch abscess. This is a localized reaction and will not jeopardize the integrity of the transmitter pouch.

A

B

Figure XII. Photographs of the antenna ports of two sheep. They demonstrate enlargement of the ports after surgical construction secondary to tissue healing contraction, and suboptimal alignment of the antenna base and the port during surgery. Optimal port construction and alignment (A) and suboptimal (B) are shown.